

**A.A. Yakushev*¹, L.Yu. Ilchenko¹, I.G. Fedorov^{1,2},
S.Yu. Orlov², G.G. Totolyan¹, I.G. Nikitin¹**

¹ — The Federal State Budget Educational Institution of Higher Education Russian National Research Medical University named after N.I. Pirogov, Department of General Medicine № 2, Advanced Course, Moscow, Russia

² — State Budgetary Healthcare Institution, City Clinical Hospital named after V.M, Department of Gastroenterology, Moscow, Russia

CASE OF CHRONIC CALCULOSIS PANCREATITIS IN PATIENT WITH ALCOHOLIC CIRRHOSIS

Abstract

The article describes clinical features, differential diagnosis and treatment of the patient with chronic calcific pancreatitis (HCP) and alcoholic liver cirrhosis (LC). The etiologic role of chronic alcohol intoxication in the development of these diseases is discussed. The patient has a history of long-term use of alcoholic beverages at hepatotoxic doses and smoking. Patient was examined before admission to our clinic. Chronic heart failure, nephrotic syndrome, paraneoplastic syndrome were excluded as the cause of generalized edema.

Patient R. was admitted to the Gastroenterology Department with ascites of unknown etiology. The severity of the patient's condition was caused by malabsorption syndrome and hepatocellular insufficiency leading to the development of edema-ascitic syndrome and trophological insufficiency. The decrease of protein levels (total protein — 38 g / l), low of albumins (14 g \ l) was observed. EGDS showed signs of portal hypertension: 1 degree esophageal varices, portal gastropathy; In addition, an increase in the size of the papilla of Vater. To clarify the nature of the pancreas damage endoscopic ultrasound was performed, which revealed multiple calcifications in the pancreas tissue. To resolve biliary hypertension stenting of the common bile duct was performed. Pancreatic duct drainage failed due to the presence of calculus at the level of the isthmus. The preferred method of treatment for the patient is Roux-En-Y hepaticojejunostomy. This case demonstrates social importance of HCP and LC combination, which leads to reduced quality of life, early disability, reduced life expectancy, as well as to an increase in treatment costs.

Key words: *calcific pancreatitis, alcoholic cirrhosis*

For citation: Yakushev A.A., Ilchenko L.Yu., Fedorov I.G., Orlov S.Yu., Totolyan G.G., Nikitin I.G. CASE OF CHRONIC CALCULOSIS PANCREATITIS IN PATIENT WITH ALCOHOLIC CIRRHOSIS. The Russian Archives of Internal Medicine. 2018; 8(1): 66-70. [In Russian]. DOI: 10.20514/2226-6704-2018-8-1-66-70

DOI: 10.20514/2226-6704-2018-8-1-66-70

EV — esophageal varices, DD — duodenum, PH — portal hypertension, PG — pancreatic gland, HE — hepatic encephalopathy, CNT — connect-the-numbers test, FCS — fibrocolonoscopy, CP — chronic pancreatitis, LC — liver cirrhosis

Introduction

We know that excessive alcohol consumption is the cause of a large number of diseases (more than 60) and traumas leading to significant social and economic consequences [1]. This is an independent risk

factor leading to the development of such diseases as chronic pancreatitis (CP) and liver cirrhosis (LC). According to J. Rehm et al., 2009 [2] alcohol contributes 3.8% of all cases of death. Occurrence of CP varies from 1.6 to 23.0 cases per 100,000 people; an increase of the occurrence is observed [3].

* Contacts. E-mail: Dgin1260@yandex.ru

Both of these chronic diseases more often develop in case of prolonged alcohol intoxication (80 g/day) over the course of at least six years [4], while the risk growth is exponential and the type of the alcoholic drink makes no difference [5].

The severity of these diseases is determined based on the maintained pancreas and liver functions. In case of apparent morphological changes, the patients show aggravating impairment of protein synthesis, exocrine and endocrine insufficiency, which result in loss of quality of life and disability. Combination of CP and LC, particularly in males, leads to early disablement, reduced life span, and an increase in the costs of treatment. So this is a topical medical and social issue.

We present a case of combined pancreas and liver injury in a patient who has consumed toxic doses of alcohol for a long time.

Clinical Case

Patient R., 45 years old, was admitted to the Gastroenterology Department with Hepatological Facilities of the State Clinical Hospital n. a. V. M. Buyanov (clinical practice base of the Department of Internal Medicine (advanced course) No. 2 of the Federal State Budgetary Institution of the Higher Education Russian National Research Medical University n. a. I. I. Pirogov of Ministry of Healthcare of the Russian Federation) as part of the "Heath Capital" program.

On admission the patient complained of weakness, increased size of the abdomen, apparent leg swelling, episodes of unstable bowel movements of up to 4 to 5 times a day (where there was a tendency to constipation over the last 2 months), and loss of 12 kg weight over the 6 months prior to the hospitalization.

The medical history includes information on prolonged consumption of drinks with high alcohol content at a dose of about 60 g/day and smoking (pack-year index of 25). The patient suffered from hepatitis A in childhood.

In 2005, he underwent pancreatic drainage indicated due to pancreonecrosis. In 2007, the patient had an episode of a significant jaundice; during the following years increased cytolytic enzymes activity (up to 4 norms from the upper threshold) was periodically observed.

The current aggravation started in 2016 and included leg swelling and development of ascites and anasarca in spring, 2017. Examinations performed at the local hospital demonstrated changes in the following biochemical blood parameters: hypoproteinemia (56 to 37 g/l), hypoalbuminemia (15 g/l); no other deviations were detected. Esophagogastroduodenoscopy (EGD) showed small bulging in the area of major duodenal papilla without exophytic growth, and FCS showed small polyps in the various sections of the colon. The additional examination including EchoCG, abdominal cavity MRI, diagnostic laparocentesis, sternal biopsy, determination of 24-hour proteinuria, etc., made it possible to rule out congestive heart failure as well as nephrotic and paraneoplastic syndromes as the cause of swelling and ascites syndromes.

The local hospital diagnosed chronic biliary pancreatitis and ascites of unclear etiology. A conservative therapy (pancreatine, torsemide, spironolactone) had no effect. The decision was made to perform laparocentesis to treat the refractory ascites. The procedure was complicated with perforation of the jejunum wall and subsequent plication thereof.

When the patient was admitted to our department (November 2017), his condition was assessed as moderate. Examination results: normosthenic constitution, decreased nutrition (BMI 18 kg/m²); muscle hypotrophy of the upper pectoral arch; edema of lower limbs up to the hips and scrotum, ascites, and anasarca. Skin and scleras are of normal color, watch-glass nails. A postoperative scar, 20 cm in length, along the white line, and venous collaterals on the lateral walls of the abdomen were observed. Auscultation shows reduced breath sounds in the lower parts of the lungs as well as no rales in the lungs. Respiratory rate was 22 breaths per minute. The peripheral blood was saturated with oxygen for 96%. No abnormalities were found in the cardiovascular system. The abdomen was distended, and free fluid was determined by percussion. Palpation of the liver and spleen was impossible due to ascites and flatulence. The liver size determined by Kurlov method was 13 × 9 × 10 cm. Urination was free, and CVA tenderness was negative at both sides.

Examination Results

The patient underwent complex clinical, laboratory and instrumental examination.

There were no significant abnormalities found in the total blood count and urinalysis. Only relative lymphopenia was noted.

The biochemical blood analysis showed such pathological changes as significant hypoproteinemia (total protein was 38 g/l), hypoalbuminemia (14 g/l) and hypocholesterolemia (2.0 μ mol/l). HbA1c level was 5.2%. A coagulogram showed reduced Quick value of 58.50%, INR 1.390, content of D-dimers of 1,150 ng/ml.

A stool test showed a significant amount of fatty acids, extracellular amyllum, and bacteria (bacilli and cocci). Taking into consideration clinical and biochemical data, the patient was diagnosed with stage II trophological insufficiency according to V. M. Luft [6]. Blood tests for cancer-specific markers demonstrated increased CA 125–285.5 U/ml (normal level is up to 35 U/ml), and CA 19-9, PSA, CA 72-4, and AFP were within the reference range.

A count-the-numbers test (CNT) showed a mild hepatic encephalopathy (HE) (CNT 62 s).

X-ray of the lungs demonstrated a hemidiaphragm elevated up to the 5th to 6th ribs as well as bilateral pleural effusion. US of the abdominal cavity showed free fluid; heterogenous liver structure with fibrosis areas; a suspension in the gallbladder; the pancreas was not satisfactory visible; an interintestinal formation containing fluid (176 × 102 × 128 mm) in the right mesogastrium.

To clarify the parameters of the pancreas changes we performed an abdominal cavity enhanced-CT (100 ml of Scanlux-370). The CT confirmed the presence of free fluid in the abdominal cavity, encapsulated liquid formations, diffuse changes in liver as well as apparent degenerative changes in pancreas such as multiple “lumpy” calcifications of the structure.

EGD showed signs of portal hypertension (PH) such as esophageal varices of the stage I and portal gastropathy. In addition, an increase of the major duodenal papilla dimensions (up to 12 mm) was noted. Visually, its orifice is swollen and includes section of hyperplasia with lobulation.

Endoscopic US was performed to complete the examination. At the level of the intrapancreatic

section, the bile duct has a relatively compressed narrowed structure (3 mm), upper bile duct has width of up to 8 mm; common hepatic duct is 8.5 mm; the duct wall is not thickened along the entire length; it has three layers and non-echogenic lumen. Contours of the pancreas are clear and uneven, and the echostructure is changed due to presence of multiple hyper-echogenic inclusions of uneven rounded form of 5 to 8 mm with or without acoustic shadows; visible parenchyma has apparently low echogenicity and heterogenous structure. In the area of the pancreas head at the outlet third part of the duct of Wirsung, an oval concrement of 8 mm diameter is detected. One more concrement of up to 8 mm in size is located more distally, and both concretions have an acoustic shadow. The duct of Wirsung is in the head of the pancreas, has a form of a moderately curved tubular structure of up to 8 mm. Distally from the isthmus it is up to 9 mm in width, and its lumen is heterogenous. The parenchyma in the body of the gland is atrophic, the body width is up to 12 mm; there are multiple concretions along the duct wall, in its lumen and lateral branches (up to 3 to 5 mm); the lateral branches are dilated and curved. The duct wall is hyperechogenic, uneven, with calcification inclusions in walls (Figure 1).

In paraduodenum, slightly below the papilla, in the duodenum wall there are two adjacent cystic inclusions of up to 2 cm in size (Figure 2).

An ERCP examination was performed with regard to the pancreatic and biliary hypertension and followed with a stenting of the bile duct with a polymer stent of 8 cm in length, 10 F diameter. When the conducting system was removed, the bile containing air bubbles vigorously flew via the stent. It was not possible to drain the pancreatic duct since it was obstructed with a concrement at the isthmus level.

Based on the performed examination, chronic metabolic pancreatitis caused by intoxication, stage C3 as per Buchler [7], alcoholic LC, class B as per Child-Pugh (score 7) was diagnosed.

The course of the disease was complicated by the calcification in the pancreas stroma, lithiasis of the duct of Wirsung, stenosis of the bile duct distal section, pancreatic and biliary hypertension, formation of the biliary sludge (gallstone disease, stage I), and papillary cysts of the duodenum walls. In addition, the classical complications of LC were detected: stage I esophageal varices, portal gastropathy,

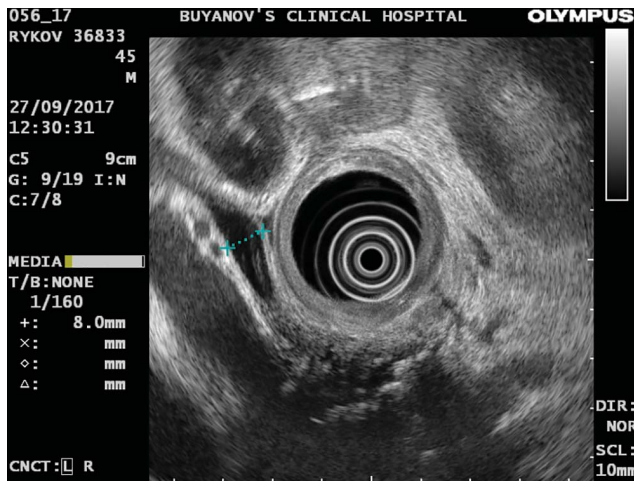


Figure 1.

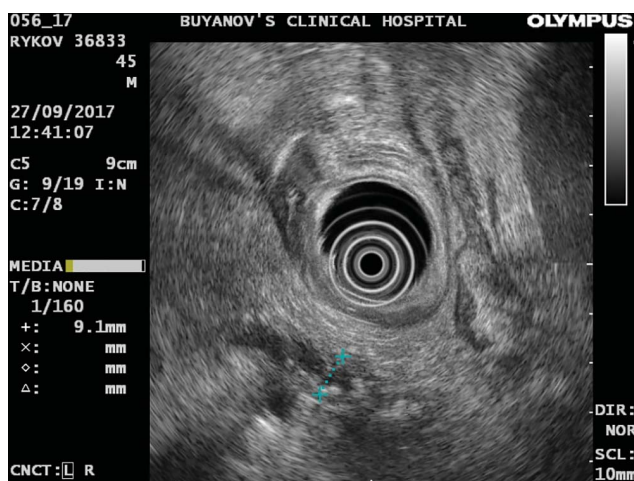

Figure 2.

swelling and ascites syndromes, bilateral pleural effusion, and significant liver dysfunction (hypoalbuminemia, hypocoagulation, stage 1 HE). Furthermore, multiple surgeries (2005 and 2017) resulted in onset of abdomen cavity peritoneal adhesions.

The patient R. was treated with diuretics, aldosterone antagonists, non-selective β -blockers, enzymes, spasmolytics, vitamins, and parenteral nutrition, including repeated albumin transfusions. In the course of the prescribed treatment, the patient reported a decrease in weakness, and swelling and ascites syndrome regressed. The patient's weight increased by 3 kg.

The following advice was given at discharge: changes in the lifestyle (completely stop smoking and drinking alcohol), bland diet (half portions with a sufficient amount of proteins), high-dosage enzyme replacement therapy and diuretics, non-selective β -blockers, hepatoprotectors, and food supplements. Follow-up is continuing.

Discussion

The patient R. was diagnosed with a combined injury of the pancreas and liver as the result of complications.

The disease severity was conditioned by malabsorption syndrome and significant impairment of the protein synthesis liver function, which resulted in the trophological insufficiency and development of swelling and anasarca. It is known that trophological insufficiency in CP patients aggravates impairment of the pancreas exocrine function and promotes a “vicious circle” formation [8]. In addition, hypoproteinemia was a major manifestation of the above mentioned pathological processes.

The differential diagnosis included a range of diseases, some of which had been already excluded at the pre-hospitalization stage. Thus, EchoCG demonstrated an unchanged ejection fraction and normal volume of the heart cavities, absence of valve regurgitation.

Peritoneal adhesions that developed after surgeries and that were confirmed by the results of the visualization methods (encapsulated liquid formations in the abdominal cavity showed by US and CT) were manifested as constipation and obscured CP and LC clinical patterns.

During the course of examinations, no evidence of neoplastic process was found, and the increased level of CA 125, apparently, was caused by the chronic inflammation process in the abdominal cavity [9]. CP was diagnosed based on the medical history and the results of laboratory and instrumental examinations.

According to M. W. Buchler et al., 1992 [10]; J. Izbicki et al., 1995 [11], an episode of acute pancreatitis leads to significant structural changes in the pancreas. A chronic inflammation of the pancreas head results in narrowing of the major pancreatic duct, cysts formation and, finally, in calcification of tissues along with the exocrine insufficiency onset. These changes were noted in patient R. based on the results of endoscopic US and CT. Calcifications in the various pancreas sections are a pathognomonic sign of the complicated CP course [5]. As we observed, the morphological changes in the pancreas led to significant exocrine insufficiency and biliary hypertension, which aggravated the course of the disease, and, moreover, represented a risk

of both jaundice onset and recurrent episodes of pancreonecrosis.

In the course of the examination, patient R. demonstrated symptoms, which are not typical for CP such as hypoalbuminemia, coagulopathy, esophageal varices, portal gastropathy, i.e. signs of LC.

One of the signs of the complicated LC course is hepatocellular insufficiency. As we observed, the significant manifestation of hypoalbuminemia was conditioned by the LC and CP combination.

As the result of pancreatic duct obstruction, the applied methods of the conservative treatment had no effect. In such cases, endoscopic stenting helps to solve the problem effectively [12].

However, presence of a concrement at the place of the desired stent location in our case made it impossible to ensure complete relief of pancreatic hypertension. Roux-En-Y hepaticojejunostomy should be considered as a method of treatment. It is currently preferred if the patient has no pain syndrome [13].

Conclusion

The cause of LC and CP in patient R. was chronic alcoholic intoxication. According to the international and Russian guidelines, alcohol has an equally negative impact on the pancreas and liver tissues. Currently discussions are being held about what is the ethanol dosage that will result in irreversible changes in the pancreas. Thus, according to the pan-European guidelines, it is 80 g/day [5]. However, according to meta-analysis performed by N. M. Irving, 2009, this dose may only be 40 g/day [14].

Taking into account the episode of pancreonecrosis in 2005, it is considered that alcohol in high doses triggered not only morphological changes but also hepatobiliary system changes in patient R.

Combined injury of the pancreas and the liver had mutually negative influence on the course of the disease. Development of such pronounced hypoalbuminemia (14 g/l) in absence of adequate drug and surgical treatment determines prognosis letalis in a patient with calculous pancreatitis and LC.

Conflict of interests

The authors declare no conflict of interests.

References:

1. WHO. Global Status Report on Alcohol and Health. 2011 URL: www.who.int/substance_abuse/publications/global_alcohol_report/msbgsruprofiles.pdf
2. Rehm J., Mathers C., Popova S., et al. Global burden of disease and injury and economic cost attributable to alcohol use and alcohol-use disorders. *Lancet*. 2009; 373: 2223–2233.
3. Dufour M.C., The epidemiology of alcohol-induced pancreatitis. *Pancreas*. 2003; 27: 286–290.
4. Maruyama K.M., Incidence of alcoholic pancreatitis in Japanese alcoholics: survey of male sobriety association members in Japan. *Pancreas*. 2007; 34: 63–65.
5. Löhr J.M., Dominguez-Munoz E., Rosendahl J. et al. HaPanEU/UEG Working Group. United European Gastroenterology evidence-based guidelines for the diagnosis and therapy of chronic pancreatitis (HaPanEU). *United European Gastroenterol. J.* 2017; 5: 153-199.
6. Luft V.M., Tkachenko E.I. Trophic failure and its diagnostics. *Military medical journal*. 1993; 12: 21-24 [in Russian].
7. Buchler M.W., Friess H., Uhl W., Malferteiner P., Chronic pancreatitis: Novel concepts in biology and therapy. A blackwell publishing company. 2002; 614 p.
8. Gavrilina N.S., Sedova G.A., Kosyra S.D., Malnutrition in patients with chronic pancreatitis. *Lechebnoe delo*. 2015; 1: 122-128 [in Russian].
9. Sergeeva N.S., Marshutina N.V., The place of serological biomarkers in oncology. *Practical oncology*. 2011; 4: 141-154 [in Russian].
10. Büchler M., Weihe E., Friess H. et al. Changes in peptidergic innervation in chronic pancreatitis. *Pancreas*. 1992; 7: 183–191.
11. Izbicki J.R., Bloechle C., Knoefel W.T. et al. Duodenum-preserving resection of the head of the pancreas in chronic pancreatitis. A prospective, randomized trial. *Ann Surg* 1995; 221: 350–356.
12. Bydzinskii A.A., The treatment of pancreatitis by dint of endoscopic methods. Transcutaneous and intracavity endoscopies interventions in surgery: sci.-practice conference, Moscow, november 12. 2010. Moscow state university of medicine and dentistry. P. 55-59 [in Russian].
13. Tretyac S.I., Rashinskaya N.T., Results of surgery treatment of biliary complications in patients with chronic pancreatitis. *Medical journal*. 2013; 3: 95-98 [in Russian].
14. Irving H.M., Samokhvalov A.V. Alcohol as a risk factor for pancreatitis. A systematic review and meta-analysis. *JOP. J Pancreas (Online)* 2009 Jul 6; 10(4): 387-392.

Ⓐ

Article received on 09.01.2018

Accepted for publication on 25.01.2018